

# Variations in Renal Arteries- A Cadaveric Study in Telangana, India

PARIMALA SIRIKONDA<sup>1</sup>, MARIYA<sup>2</sup>, RAJU SUGAVASI<sup>3</sup>, RAJA SEKHAR KATIKIREDDI<sup>4</sup>

## ABSTRACT

**Introduction:** Regarding the disorders associated with multiple renal arteries, they are of specific interest to urologists, nephrologists, surgeons and radiologists.

**Aim:** To identify the presence of multiple renal arteries in the human cadavers.

**Materials and Methods:** An observational cadaveric study was conducted on 50 formalin-fixed human cadavers in Osmania Medical College, Hyderabad, Telangana, India, from May 2017 to July 2022. Dissection procedure was followed according to standard techniques. Variations and patterns of renal arteries were observed. Descriptive statistics were used and results were expressed in terms of frequency (N) and percentages (%).

**Results:** Out of 50 cadavers, variations in the renal artery were seen in eight cadavers. Four cadavers showed double renal arteries (one right side and three left side). Three cadavers showed early division and one cadaver which has shown double Right Renal Artery (RRA) also showed Early Division of RRA (ED of RRA) and one cadaver showed an Accessory Renal Artery (ARA) on the left side.

**Conclusion:** Variations observed were mainly double renal arteries, early division of the renal arteries and ARA. This kind of different pattern of variations may play an important role in renal transplants and any surgeries involving the renal arteries.

**Keywords:** Accessory renal artery, Patterns, Renal transplant, Segmental branches

## INTRODUCTION

A 20% of cardiac output is sent to the kidneys for filtration through the right and left renal arteries [1]. Typically, the renal arteries begin as a lateral branch of the abdominal aorta right below the superior mesenteric artery (L1-L2), and they split into an anterior and posterior branch close to the hilum. Because the abdominal aorta is on the left side and is located at a higher level than the Left Renal Artery (LRA), the Right Renal Artery (RRA) is somewhat longer than the LRA in most of the people [1]. In about 70% of cases, just one renal artery emerges from the abdominal aorta to supply the kidney. Yet, numerous researchers have noted, differences in renal artery origin and number [2-4]. The precise relationship, size, obliquity, quantity and level of origin of the renal arteries can vary [3]. Lateral origin (92%) of renal arteries is most commonly observed compared to anterolateral (6%) and posterolateral (2%) which are less common origins, from the abdominal aorta at the level of L1-L2 [1]. Racial, ethnic and social differences were highlighted by the frequencies of renal artery changes, with variations in the artery's branching pattern being more common in Africans and less common in Indians [5]. The auxiliary renal artery and early branching into segmental arteries, before reaching the hilum are the two main categories of renal artery variations [6]. The morphology of the renal arteries is crucial for choosing kidney donors because it affects kidney transplant procedures and reduces vascular trauma [7].

Various authors have studied the variations in renal vascular patterns and noted the incidence of accessory renal arteries varying widely with ethnicity [4,6]. Hence, the author wanted to determine the variations in renal arterial patterns in the Telangana region, so the present study was conducted.

## MATERIALS AND METHODS

An observational cadaveric study was conducted on 100 kidneys from 50 formalin-fixed human cadavers from May 2017 to July 2022 in the Department of Anatomy, Osmania Medical College, Telangana, India. The number of cadavers showing variations of renal arteries was determined.

**Inclusion and Exclusion criteria:** Good and well formalin-fixed cadavers were included in the study and traumatised ones were excluded.

## Study Procedure

Standard dissection was performed. Cunningham's manual for anatomy dissection was followed for dissection [8]. The abdomen was dissected and the branches of the aorta were traced. The right and left renal arteries were exposed and followed to the kidneys. The length of the abnormal renal artery was measured with inch tape from the origin to its division into branches, if the main renal artery was dividing into segmental branches within 1 cm from its origin, it is called as early division and additional vessels from abdominal aorta which supply to kidney, is called as ARA, which forms during the ascent of kidney [9]. If more than two vessels supply the kidney from abdominal aorta, it is called a double renal artery [6]. The number and course of both the right and left renal arteries were noted. Photographs were taken and analysed.

## STATISTICAL ANALYSIS

Descriptive statistics were used and results were expressed in terms of frequency (N) and percentages (%).

## RESULTS

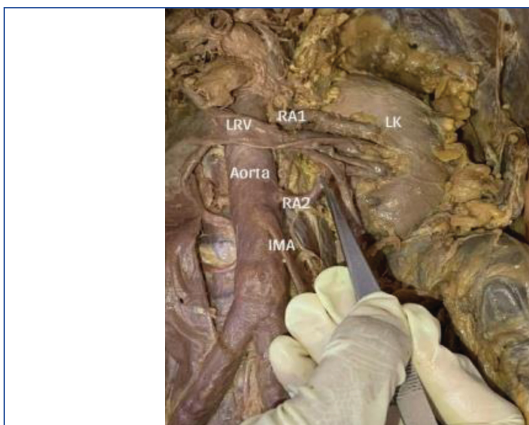
The variations seen in the eight cadavers were as follows:

**Cadaver 1:** The [Table/Fig-1] showed a double renal artery on the left side. Left gonadal artery was not seen branching from aorta, instead it is given off from the internal Iliac artery on the left side.

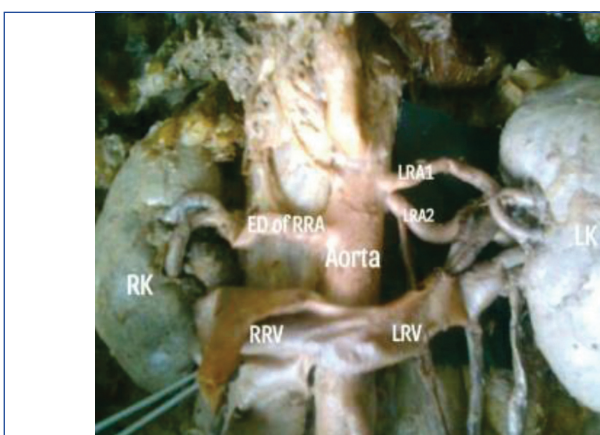
**Cadaver 2:** The [Table/Fig-2] showed a double renal artery on the left side and Early Division (ED) of RRA.

**Cadaver 3:** The [Table/Fig-3] showed double renal artery was seen on the right side.

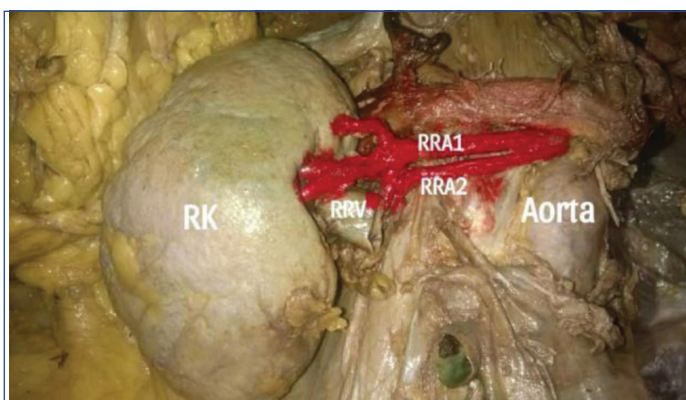
**Cadaver 4:** The [Table/Fig-4] showed a double renal artery seen on the left side.



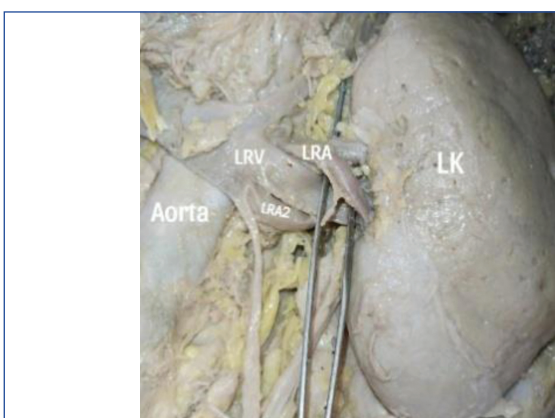
**[Table/Fig-1]:** Double renal artery seen on the left side {LRA: Left renal artery; LK: Left Kidney; LRV: Left renal vein; IMA: Inferior Mesenteric Artery} Left gonadal artery was not seen branching from aorta instead, it is given off from internal iliac artery on the left side.



**[Table/Fig-2]:** Double renal artery seen on the left side and early dissection of the Right Renal Artery (RRA) (ED of RRA=Early dissection of Right renal artery, LRA=Left renal artery, LK=Left kidney, RK=Right kidney, LRV=Left renal vein, RRV=Right Renal vein).



**[Table/Fig-3]:** Double renal artery seen on the right side. {RRA=Right renal artery (RRA), RK=Right kidney, RRV=Right renal vein}.



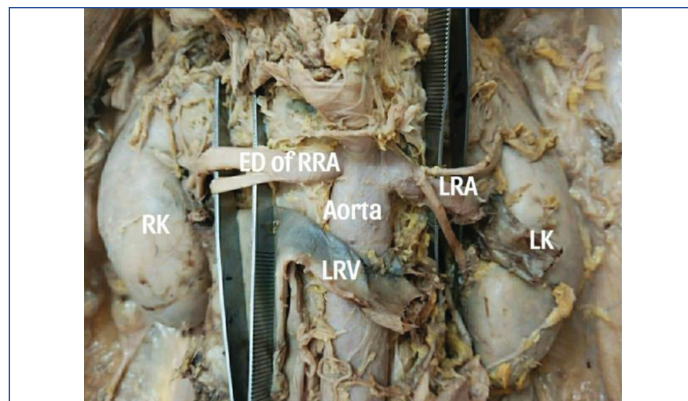
**[Table/Fig-4]:** Double renal artery seen on the left side {LRA=Left renal artery, LK=Left kidney, LRV=Left renal vein}.

**Cadaver 5:** The [Table/Fig-5] showed ED of RRA and normal LRA.

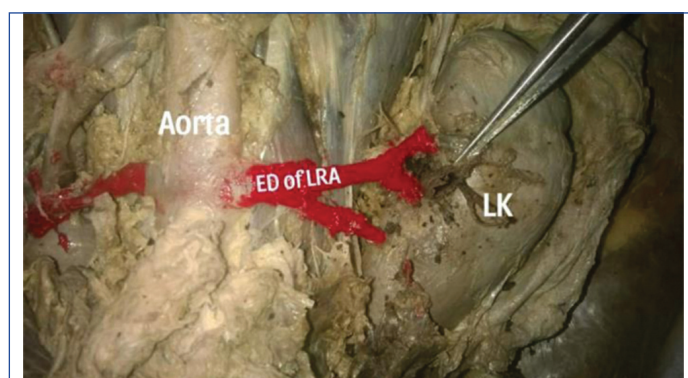
**Cadaver 6:** The [Table/Fig-6] showed early division of the renal artery was seen on the left side and RRA was normal.

**Cadaver 7:** The [Table/Fig-7] showed ED of RRA.

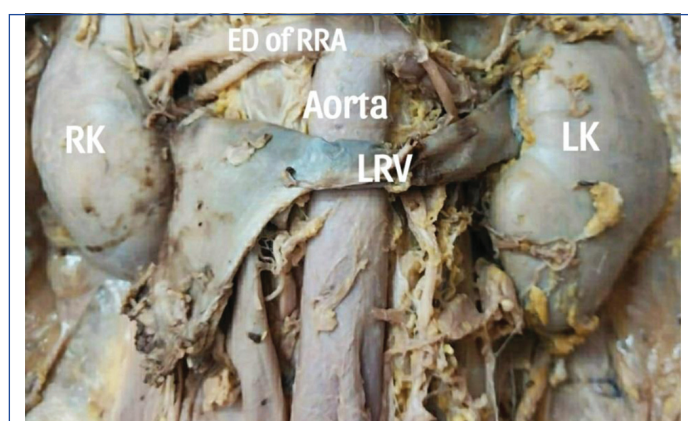
**Cadaver 8:** The [Table/Fig-8] showed Accessory Renal Artery (ARA) was seen on the left side.



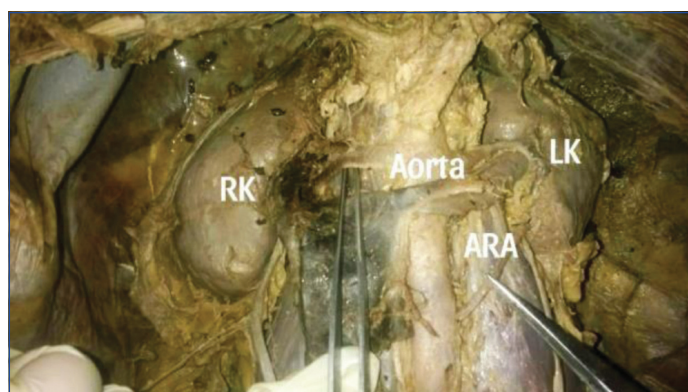
**[Table/Fig-5]:** Early Dissection of the Right Renal Artery (ED of RRA) and normal Left Renal Artery (LRA).



**[Table/Fig-6]:** Early Division of the Left Renal Artery (ED of LRA) and normal Right Renal Artery (RRA).



**[Table/Fig-7]:** Early Dissection of the Right Renal Artery (ED of RRA).



**[Table/Fig-8]:** Accessory Renal Artery (ARA) seen on the left side.



Out of 50 cadavers, variations in the renal artery were seen in eight cadavers [Table/Fig-9].

S. No.	Variations in the renal artery	Number of cadavers
1.	Early division	4 (3 right, 1 left)
2	Double renal artery	4 (1 right, 3 left)
3	Accessory renal artery (ARA)	1 (left side)

**[Table/Fig-9]:** Number of variations in the renal artery.  
In one cadaver two findings were noted

## DISCUSSION

The present study focused on morphological and gross variations in anatomical aspects of renal arteries and their clinical correlations. The causative factor for the variations may be the persistence of embryological vessels which arises from the abdominal aorta, these are lateral branches of mesonephros within the renal ascent [10]. Khmanarong K et al., found 17% of double renal arteries in their study on Thai cadavers and the present study showed 8% of double renal arteries in south Indian population of Telangana [11]. This difference could be due to the geographical variation. Sabec-Pereira DK et al., published a case report with double renal artery in two out of four urinary blocks in it [12]. A communication delay between the mesenchyme of the blood vessel and the mesenchyme of the metanephros, such as that caused by glial-derived neurotropic factor and hepatocytic growth factor, may have contributed to the earlier division [13]. Because the surgeon would not have a lengthy pedicle to anastomose the renal artery, the early division of the renal artery is not advantageous for transplantation [14]. When the renal artery length was less than 1.5 cm, it was considered an early division [9]. Panchal P and Singh S, found early division of the renal artery in three cadavers, which is a part of the case series [15]. The present study showed early division of the renal arteries in four out of 50 cadavers. Three in the Right Kidney (RK) and one in Left Kidney (LK). Anomalous variations in renal vasculature are common because of the complex nature of renal embryogenesis. ARAs are extra arteries that may branch off from the primary artery at the hilum or enter the parenchyma on their own. ARAs with "extra hilar" penetrations usually act as end-arteries, which are anastomose free, tissue sustaining conduits. As a result, injuring or ligating these ARAs will inevitably result in an infarction of the renal parenchyma that they supply [16].

Accessory renal arteries are a common variant of the renal arteries. They are present in ~25% (range 20-30%) of the population and bilateral in ~10% [1]. Özkan U et al., found accessory renal arteries in 6% of their patients from turkey in their study using an angiogram [17]. In the present study, ARA supplying the lower pole of LK was found in one out of 50 cadavers. The study by Maheswararao SU et al., found that supernumerary renal arteries emerging from the aorta were present in 50% of patients, with 30% of cases occurring on the right side and 20% on the left [18]. According to Munnusamy K et al., renal arteries varied in 51% of the population, with 38% of people having auxiliary renal arteries and 13% having an early renal artery division [19]. Gumus H et al., reported ARA and early division in 27% of cases [6]. Sumalatha T and Pushpamala N, reported accessory renal arteries in 23.3%, of which 8.3% were right sided [20]. Rajakumari SN and Arumugam K, found the early division of renal arteries in 10%, accessory renal arteries in 30%, and aberrant renal arteries in 22% of cadavers studied [21]. Nagajyothi D et al., detected accessory renal arteries in 13.3% cadavers [22]. Mutnuru PC et al., reported single ARA in 16% and multiple unilateral/bilateral renal arteries in 2% [23]. According to the present study,

variations in renal artery were seen in 8 (16%) cadavers, which included four early division, four double renal arteries and one ARA {1 cadaver which had double renal artery also showed early division}. The incidence of accessory renal arteries varies widely with ethnicity, ranging from 11.4% in Kenyans to 59.5% in Indians [23]. Information related to renal vasculature and anomalies is required by the surgeons before surgery, in order to minimise the trauma to vessels during surgeries.

**Absent gonadal arteries:** If one or both testicular arteries are missing, the testes are supplied by branches from the vesical or prostatic arteries passing under the arch of the pubis [24]. The present study showed one cadaver with absent bilateral gonadal arteries [Table/Fig-8].

## Limitation(s)

The study was done on the cadavers and also the sample size was limited to generalise the results. It can be extended at the level of radiological and genetic grounds, to obtain further results and conclusions.

## CONCLUSION(S)

The existence and identification of abnormal renal artery variations play an important role in renal surgeries like renal trauma, vascular embolisation, renal angioplasty, and kidney transplantations.

## REFERENCES

- [1] Susan Standring. Gray's Anatomy. The Anatomical Basis of Clinical Practice Vol. 42. Churchill Livingstone; 2008. Pp. 1183.
- [2] Shakeri AB, Tubbs RS, Shoja MM, Pezeshk P, Farahani RM, Khaki AA, et al. Bipolar supernumerary renal artery. Surg Radiol Anat. 2007;29(1):89-92.
- [3] Rao M, Bhat SM, Venkataramana V, Deepthinath R, Bolla SR. Bilateral prehilal multiple branching of renal arteries: A case report and literature review. Kathmandu University Medical Journal (KUMJ). 2006;4(3):345-48.
- [4] Satyapal KS, Haffeejee AA, Singh B, Ramsaroop L, Robbs JV, Kalideen JM. Additional renal arteries incidence and morphometry. Surgical and Radiologic Anatomy. 2001;23(1):33-38.
- [5] Kadir S. Atlas of normal and variant angiographic anatomy. Philadelphia: W.B. Saunders Company; 1991. Kidneys. In: Kadir S, ed; pp. 387-429.
- [6] Gumus H, Brdal Ozdemir E, Cetincakmak ML, Tekbas G, Ekici, Onder H, et al. Variations of renal artery in 820 patients using 64-detector CT-Angiography. Renal Failure. 2012;34:286-90.
- [7] Boijesen E. Abrams' angiography. 4th ed. Philadelphia: Little, Brown and Company; Renal angiography: Techniques and hazards; anatomic and physiologic considerations. 1997. In: Baum S, ed; Pp. 1101-31.
- [8] Cunningham's Manual of Practical Anatomy. Vol. 2. 15th ed. New York: Oxford Medical Publications; 1986; Pp.169-77.
- [9] Çınar C, Türkvtan A. Prevalence of renal vascular variations: Evaluation with MDCT angiography. Diagn Interv Imaging. 2016;97(9):891-97.
- [10] Langman J, Sadler TW. Embryologie Médicale. Paris, Pradel. 1996;301.
- [11] Khmanarong K, Prachaney P, Utravichien A, Tong-Un T, Sriporaya K. Anatomy of renal arterial supply. Clinical Anatomy: The Official Journal of the American Association of Clinical Anatomists and the British Association of Clinical Anatomists. 2004;17(4):334-36.
- [12] Sabec-Pereira DK, Campos TD, Pereira KF, Lima FC, Rita RD, Gutierrez OB. Double renal artery in human cadavers: A case report. Biosci J. (Online). 2017;33(6):1666-70.
- [13] Ferrara N. Role of vascular endothelial growth factor in the regulation of angiogenesis. Kidney International. 1999;56(3):794-814.
- [14] Weld KJ, Bhayani SB, Belani J, Ames CD, Hruby G, Landman J. Extrarenal vascular anatomy of kidney: Assessment of variations and their relevance to partial nephrectomy. Urology. 2005;66(5):985-89.
- [15] Panchal P, Singh S. Prehilal renal artery division with supernumerary renal veins: A case series. Int J Anat Var. 2017;10(3):39-42.
- [16] Moore KL, Persaud TV, Torchia MG. Before we are born: Essentials of embryology and birth defects (with Student Consult Online Access). Elsevier Health Sciences; 2007 Oct.
- [17] Özkan U, Oguzkurt L, Tercan F, Kizilkilic O, Koç Z, Koca N. Renal artery origins and variations: Angiographic evaluation of 855 consecutive patients. Diagnostic and Interventional Radiology. 2006;12(4):183.
- [18] Maheswararao SU, Naik MN, Narasamma KC. A study of supernumerary renal arteries in South Indians. J Evid Based Med Healthc. 2016;3(62):3376-79.
- [19] Munnusamy K, Kasirajan SP, Gurusamy K, Raghunath G, Bolshetty SL, Chakrabarti S. Variations in branching pattern of renal artery in kidney donors using CT angiography. Journal of Clinical and Diagnostic Research. 2016;10(3):AC01-03.
- [20] Sumalatha T, Pushpamala N. Accessory renal arteries a cadaveric study. Indian Journal of Anatomy. 2018;7(5):528-32.

- [21] Rajakumari SN, Arumugam K. Cadaveric study of renal artery variations. International Journal of Contemporary Medical Research. 2019;6(12):L1-L3.
- [22] Nagaiyothi D, Panduranga G, Saritha S. Renal vasculature: Wide spectrum of anatomical variations with embryological background and focus on surgeon's point-a cadaveric study. Journal of Pharmaceutical Negative Results. 2022;13(7):4769-76.
- [23] Mutnuru PC, Susarla R, Devraj R. Incidentally detected anomalous renal arteries during angiogram- a case series. J Clin Diagn Res. 2022;16(8):TR01-TR03.
- [24] Bergman RA, Afifi AK, Miyauchi R. Gonadal (ovarian and spermatic or testicular) Arteries. Anatomy Atlases [online]. Available at: [www.anatomyatlases.org/AnatomicVariants/Cardiovascular/Text/Arteries/Gonadal.html](http://www.anatomyatlases.org/AnatomicVariants/Cardiovascular/Text/Arteries/Gonadal.html). Accessed May. 2006;1.

**PARTICULARS OF CONTRIBUTORS:**

1. Assistant Professor, Department of Anatomy, Osmania Medical College, Hyderabad, Telangana, India.
2. Assistant Professor, Department of Anatomy, Osmania Medical College, Hyderabad, Telangana, India.
3. Associate Professor, Department of Anatomy, Fathima Institute of Medical Sciences, Kadapa, Andhra Pradesh, India.
4. Assistant Professor, Department of Anatomy, Gandhi Medical College, Hyderabad, Telangana, India.

**NAME, ADDRESS, E-MAIL ID OF THE CORRESPONDING AUTHOR:**

Dr. Raja Sekhar Katikireddi,  
301/B, Rockcliffthirtha Apartment, Dwarakamai Nagar, Bandlaguda Jagir,  
Gandipet Mandal, Rangareddy District, Hyderabad-500086, Telangana, India.  
E-mail: drkrs27@gmail.com

**PLAGIARISM CHECKING METHODS:** [\[Jain H et al.\]](#)

- Plagiarism X-checker: Oct 03, 2022
- Manual Googling: Mar 13, 2023
- iThenticate Software: Mar 15, 2023 (14%)

**ETYMOLOGY:** Author Origin**AUTHOR DECLARATION:**

- Financial or Other Competing Interests: None
- Was informed consent obtained from the subjects involved in the study? NA
- For any images presented appropriate consent has been obtained from the subjects. NA

Date of Submission: **Sep 30, 2022**Date of Peer Review: **Dec 01, 2022**Date of Acceptance: **Mar 16, 2023**Date of Publishing: **May 01, 2023**